





TASHKENT MEDICAL ACADEMY

100 TMA
ANNIVERSARY



Journal of Educational and Scientific Medicine



Issue 2 (2) | 2023



OAK.UZ
Google Scholar

Supreme Attestation Commission of the Cabinet
Ministry of the Republic of Uzbekistan

ISSN: 2181-3175

Modern Information on the Etiology of Necrotizing Fasciitis

D.N. Korikhonov¹

ABSTRACT

Necrotizing fasciitis is an infectious disease of fascial structures, the origin of which is associated with the penetration of an infectious agent into the circulating blood (infection of circulating blood) through damaged skin. The source of infection can be abrasions, abrasions, wounds, including operating ones, including laparoscopy, burns, as well as purulent diseases of various organs. The mechanism of interaction of the microbial factor initiating necrotizing fasciitis with the macroorganism is fundamentally different from the pathogenesis of banal infectious diseases of soft tissues. The purpose of this article is to characterize the microbiota of necrotizing fasciitis based on data from various publications and analysis of our observations.

Keywords: necrotizing fasciitis, etiology, microflora, sepsis

The most common causative agents of skin and soft tissue infections are *Str. pyogenes* and *Staph. aureus* [38] – Table-1.

The spectrum of these infectious diseases is quite wide: from skin and cellulite to severe necrotizing fasciitis. The species structure of the microbiota is equally diverse, which can act both in the form of mono-infection and the form of its mixed forms [1-4].

The greatest difficulty for surgical practice is represented by such forms of the disease, the pathomorphological basis of which are necrotic processes, since, as a rule, they are accompanied by a severe clinical course and high mortality [18,25,31].

In the structure of these diseases, the most severe in terms of clinical course and outcomes are gas gangrene, and necrotizing fasciitis types I and II. Having excluded from this group patients with gas clostridial gangrene, which is quite well covered in publications, we chose as the subject of our research a practically new disease - necrotizing fasciitis, which is extremely poorly represented in scientific periodicals and therefore constitutes a "secret behind seven seals" for the overwhelming number of practitioners, which cannot but negatively affect the results of treatment of patients [6,10,42].

Some necrotizing infections are caused by a single microorganism. Myonecrosis (gas gangrene) caused by clostridia, and necrotizing fasciitis, the causative agent of

¹ Assistant of the Department of General and Pediatric Surgery-1 of the Tashkent Medical Academy, Tashkent, Uzbekistan. E-mail: dqorixonov@gmail.com

which is group A B-hemolytic streptococcus are classic examples of monomicrobial necrotizing infection. Recently, the frequency of reports of necrotizing fasciitis caused by group A hemolytic streptococcus has increased [13], including in pediatric practice.

Table-1. Necrotizing soft tissue infections

Type	Main etiological factors	Trigger	Clinical manifestations
Gangrene Meleney	Staph. Aureus, Streptococcus	Surgery	Slow ulceration of superficial fascia
Clostridial cellulite	Cl. Perfringes	Minor trauma, surgery	Gas in the skin, intoxication
Non-clostridial anaerobic cellulite	Mixed aerobic and anaerobic microbiota	Diabetes mellitus	Gas in tissues
Gas gangrene	Cl. Perfringes, hystoliticus	Trauma, tumors, chemotherapy	Myonecrosis, intoxication, shock
Necrotizing fasciitis type I	Anaerobes, gram-negative aerobes, enterococci	Surgery, diabetes mellitus, trauma	Necrosis of fascia and fat
Necrotizing fasciitis type II	Streptococcus A	Penetration, surgery, burns, wounds, injuries	Intoxication, shock, multiple organ failure, pain, gangrene

The most detected microorganisms include streptococci, staphylococci, Bacteroides and clostridia. Facultative microorganisms reduce the oxidant-reduction potential in the wound and create favourable conditions for the growth of anaerobes. Anaerobes affect the function of phagocytes and thus improve the proliferation of aerobes. Some bacteria, such as Bacteroides fragilis, produce B-lactam enzymes that impair antibiotic activity [23,32].

Bacterial neurotoxins that produce Cl. perfringens and Str. pyogenes, cause tissue necrosis. In addition, the infectious process activates the coagulation system, which causes local vascular thrombosis with the development of ischemic necrosis [24].

The isolated strains of pathogenic microorganisms in 80.6% of cases turned out to be multiresistant to most of the antibiotics used, which significantly complicates the cure of patients with necrotizing fasciitis [21].

In the presented figure-1, we provide static information on the species structure of the microbiota in necrotizing fasciitis, given in the works of various researchers.

When studying the causative agents of necrotizing fasciitis, a combination of non-spore anaerobes with aerobes was most often found [14].

Among strict anaerobes, Bacteroides are the most important, and among aerobes, β -hemolytic streptococci

and enterobacteria (E. Coli, Klebsiella, Enterobacter). Of interest is a microscopic picture of a smear of exudate stained according to Gram. Among the varieties of microorganisms, there are spindle-shaped gram-negative rods, individual cells have capsules and gram-positive cocci are found. Microbes fill the entire field of vision. The absence of phagocytosis was noted [39].

The species composition of the microbiota in our clinical observations (37 patients) is also diverse, with Staph. aureus and Str. pyogenes being the dominant pathogens [26].

The affected areas of necrotizing fasciitis are diverse. In almost all areas of the human body, foci of necrotic changes in fascial structures, including the head and neck, can be localized. However, purulent-necrotic processes are most often localized on the trunk (anterior and lateral walls of the abdomen, gluteal regions, limbs), scrotum (Fournier's gangrene), perineum, and less often on the chest wall [2-6].

In our observations, the localization of necrotizing fasciitis by zones is as follows: abdomen - 16, lower limbs - 10, scrotum - 6, perineum - 2, chest - 2.

Invasion of the microbiota occurs most often through damaged skin in the form of abrasions, scratches, abrasions, accidental and surgical wounds, places of infection, as well as purulent foci [3,9,16,25].

Cases of necrotizing fasciitis after laparoscopy, endoscopic gastroscopy, thoracostomy, and thoracotomy [17,34,36] have been described.

Most often, the process develops in abdominal incisions, especially if the abdominal cavity was opened. There is a high risk of developing necrotizing fasciitis in patients with peritonitis [17].

Skin gangrene (Fournier's gangrene), which is a type of necrotizing fasciitis [5,8,10-12,33,40,41], easily develops in the scrotum. In the same area, the cause of necrotizing fasciitis may be a pararectal abscess. In one of the works of foreign authors, information is presented on 10 cases of Fournier's gangrene out of 10 patients with pararectal abscesses. In our observations, Fournier's gangrene occurred in 17 patients.

Patients with necrotizing fasciitis have a very high risk of developing severe sepsis and septic shock, which ultimately leads to multiple organ dysfunction/failure associated with high mortality [14,19,20,27,28,31].

In our observations, the clinical picture of severe sepsis was noted in 27 patients. 21 of them developed infectious-toxic shock syndrome.

Bacteriological verification of sepsis by blood culture, unfortunately, does not always give a positive hemoculture result [15,22].

Firstly, because blood for hemoculture is taken most often against the background of antibiotic therapy, and secondly, in some patients the clinical course of the disease proceeded according to the type of "Syndrome toxic septic shock", which ended in death within 1-2 days. It is reported that bacteremia is extremely rare in patients with infectious-toxic shock syndrome due to necrotizing fasciitis [31]. In our opinion, this phenomenon can be explained by the fact that the shock in these cases is caused not by microbial, but by toxigenic invasion, the source of which is extensive zones of necrosis of soft tissue structures. The mechanism of action of toxicosis is like the impact of an aggressive agent on the cellular structures of the reticuloendothelial system, which may be followed by the invasion of microorganisms into the circulating blood.

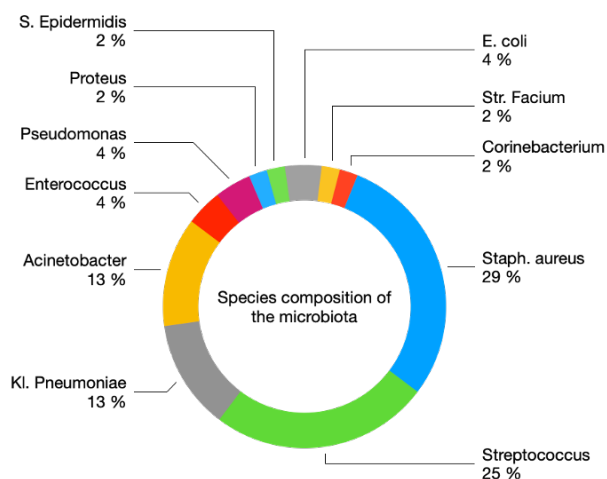


Figure 1. Species composition of the microbiota

Staphylococcus aureus prevailed in the structure of positive blood excretions in our observations.

In 18-20% of patients with necrotizing fasciitis, it is not possible to establish the source and route of infection. In such cases, they speak of idiopathic necrotizing fascia t e [35]. Of course, in this situation, we are not talking about the absence of a source of infection, but about not recognizing the primary focus, which is hidden from visual routine research methods. It seems strange, but the human perception of the relationship between "macro" (human) and "micro" (microorganism) is based, as a rule, on the fact that infection should occur and occurs only from Environment. Meanwhile, throughout his life, a person is constantly in contact with the world of microorganisms that inhabit his open cavities and, first,

the intestines. Among the most common microorganisms are gram-negative opportunistic bacteria that can cause localized purulent-inflammatory and generalized processes with a sharp weakening of immunity.

The structural component of the outer membrane of gram-negative bacteria is, as is known, endotoxin (lipopolysaccharide), which has a wide range of biological activity. He is credited with the role of a trigger of disseminated intravascular coagulation, the morphological basis of endotoxin shock, the most formidable complication of systemic endotoxemia.

The natural reservoir of a huge number of anaerobic and aerobic gram-negative bacteria is the colon. When microorganisms are destroyed, endotoxin accumulates in the lumen of the intestine. The intact mucous membrane of the colon is normally a reliable barrier that prevents the penetration of lipopolysaccharides into the blood in large quantities. But even in the conditions of practical norms, a certain amount of endotoxin still penetrates the blood. This process can intensify in the event of various injuries to the intestinal mucosa and dysbiosis, which are accompanied by the translocation of bacteria and their waste products into the small intestine. In progress Evolution, to ensure the protection of the body from death, cellular and humoral structures were formed to neutralize endotoxin that has penetrated the blood. One of the essential mechanisms of such protection is the system of fixed liver macrophages. Blockade of the macrophage system of the liver with various substances potentiates the action of endotoxin. Thus, an increase in the titer of antibodies to lipopolysaccharide in cirrhosis of the liver was noted [36,37].

Humoral factors also play an important role in the detoxification of lipopolysaccharide penetrating the circulating blood.

Thus, the body of a healthy person under normal environmental conditions is reliably protected from the action of endotoxin by the system of cellular and humoral immunity. However, in some cases, the barrier functions of these factors are impaired, which leads to the development of systemic endotoxemia. First, damage to the intestinal mucosa contributes to the development of systemic endotoxemia [7,33,40,41] in diseases such as Crohn's disease, chronic ulcerative colitis, acute intestinal infections caused by gram-negative, and gram-positive bacteria, as well as viruses. The barrier functions of the intestinal mucosa can also be damaged by disorders of the blood supply to the intestine due to surgical interventions, the development of tumours, acute and chronic alcohol intoxication, as well as stress reactions.

An important condition for the development of systemic endotoxemia is also liver disease and inhibition of the functions of the system of fixed liver macrophages, which is observed in various inflammatory bowel diseases, cholecystitis, acute destructive pancreatitis, diabetes mellitus, shock, and anesthesia.

From the foregoing, it follows that one of the sources of endotoxemia in the absence of another infectious focus is the intestine, which initiates the entry of endotoxin into the portal and systemic circulation with impaired permeability of its protective barriers. Necrotizing fasciitis, as it seems to us, is a model of a similar mechanism of infection of circulating blood, which is not visualized by routine diagnostic methods and therefore falls under the heading "idiopathic fasciitis". In subsequent publications, we intend to provide information on the detailed characteristics and mechanism of the development of necrotizing fasciitis.

Consent for publication - The study is valid, and recognition by the organization is not required. The author agrees to open the publication.

Availability of data and material - Available

Competing interests - No

Financing - Self

REFERENCES:

1. A Case Series Describing 118 Patients with Lower Limb Necrotizing Fasciitis / A. K. Khanna, S. K. Tiwary, P. Kumar [et al.] // *The International Journal of Lower Extremity Wounds*. – 2009. – Vol. 8, No. 2. – P. 112-116.
2. A fatal case of craniofacial necrotizing fasciitis / A. J. F. Beerens, L. J. Bauwens, C. R. Leemans // *European Archives of Oto-Rhino-Laryngology*. – 1999. – Vol. 256, No. 10. – P. 0506-0509.
3. A Review of Necrotizing Soft-Tissue Infections / K. W. Burchard, A. T. Mcmanus, J. M. A. Bohnen, J. M. Davis // *Sepsis*. – 1998. – Vol. 2, No. 1. – P. 79-87.
4. Cervical Necrotizing Fasciitis: Sources and Outcomes / N. Skitarelic, R. Mladina, M. Morovic // *Infection*. – 2003. – Vol. 31, No. 1. – P. 39-44.
5. Clinical study of Maggot therapy for Fournier's gangrene / A. Fonseca-Muñoz, R. Pérez-Pacheco, H. E. Sarmiento-Jiménez, et al. // *International Wound Journal*. – 2020. – Vol. 17, No. 6. – P. 1642-1649.
6. Congenital Volkmann ischaemic contracture: a case report and review / P. M. H. Cham, B. A. Drolet, A. D. Segura, N. B. Esterly // *British Journal of Dermatology*. – 2004. – Vol. 150, No. 2. – P. 357-363.
7. Craniocervical necrotizing fasciitis of odontogenic origin with mediastinal extension / J. D. Edwards, N.

Sadeghi, F. Najam // *Ear, Nose & Throat Journal*. – 2004. – Vol. 83, No. 8. – P. 579-582.

8. Emergencies in andrology / C. Bettocchi, M. Spilotros // *Clinical Uro-Andrology*, 2015. – P. 277-283.

9. Faergemann J. Facial skin infections // *PERIODONTOLOGY* 2000. – 2009. – Vol. 49, No. 1. – P. 194-209.

10. Fournier's gangrene secondary to male circumcision - a case report and review of the literature / M. Tripoli, E. Cammarata, A. Cordova // *Acta Chirurgiae Plasticae*. – 2021. – Vol. 63, No. 3. – P. 96-101.

11. Fournier's Gangrene: Report of Six Cases / T. Ochiai, K. Ohta, M. Takahashi [et al.] // *Surgery Today*. – 2001. – Vol. 31, No. 6. – P. 553-556.

12. Fournier's gangrene: still highly lethal / A. J. Papachristodoulou, G. N. Zografos, G. Papastratis [et al.] // *Langenbeck's Archives of Surgery*. – 1997. – Vol. 382, No. 1. – P. 15-18.

13. Group A streptococcal toxic shock syndrome with severe necrotizing fasciitis following hysterectomy - a case report / M. Loscar, G. Schelling, M. Haller [et al.] // *Intensive Care Medicine*. – 1998. – Vol. 24, No. 2. – P. 190-193.

14. Jimenez M. F. Source control in the management of sepsis // *Intensive Care Medicine*. – 2001. – Vol. 27, No. 14. – P. S49-S62.

15. Kasimov WK, et al. "Fargal's in the treatment of necrotic infections of soft tissues on the background of diabetes mellitus." *Open Access Repository* 4.02 (2023): 63-73.

16. Massive soft tissue infections: Necrotizing fasciitis and purpura fulminans / R. F. Edlich, K. L. Winters, C. R. Woodard [et al.] // *Journal of Long-Term Effects of Medical Implants*. – 2005. – Vol. 15, No. 1. – P. 57-65.

17. Necrotic fasciitis as a complication of acute destructive appendicitis / O. Kanadashvili, E. Belykh, M. Soborov, et al. // – 2021. – No. 311. – P. 21-27.

18. Necrotising fasciitis due to group A streptococci in western Norway: Incidence and clinical features / J. Chelsom, A. Halstensen // *The Lancet*. – 1994. – Vol. 344, No. 8930. – P. 1111-1115.

19. Necrotizing fasciitis as a rare complication of osteonecrosis of the jaw in a patient with multiple myeloma treated with lenalidomide: Case report and review of the literature / P. Mondello, V. Pitini, C. Arrigo, et al. // . – 2014. – Vol. 3, No. 1. – P. 1-5.

20. Necrotizing Fasciitis Developing from a Brown Recluse Spider Bite / J. Majeski // *American Surgeon*. – 2001. – Vol. 67, No. 2. – P. 188-190.

21. Necrotizing fasciitis is secondary to peritonsillar abscess: A new case and review of eight earlier cases /

M. A. Safak, I. Haberal, D. Kilic // *Ear, Nose & Throat Journal*. – 2001. – Vol. 80, No. 11. – P. 824-830.

22. Necrotizing Fasciitis of the Upper Extremity Resulting from a Water Moccasin Bite / M. F. Angel, F. Zhang, M. Jones // *Southern Medical Journal*. – 2002. – Vol. 95, No. 9. – P. 9010-9014.

23. Necrotizing fasciitis: A diagnostic challenge / D. L. Meltzer, M. Kabongo // *American Family Physician*. – 1997. – Vol. 56, No. 1. – P. 145-149.

24. Necrotizing fasciitis: Improved survival with early. / J. Majeski, E. Majeski // *Southern Medical Journal*. – 1997. – Vol. 90, No. 11. – P. 1065-1068.

25. Necrotizing Soft Tissue Infection - An Increasing Problem in Orthopedic Trauma / N. Schwarz, H. Redl, H. Grasslobler, B. Krebitz // *European Journal of Trauma*. – 2000. – Vol. 26, No. 2. – P. 62-68.

26. Nothwang J. Necrotising fasciitis-cryptogenic infection following posttraumatic immunopathy? // *Archives of Orthopaedic and Trauma Surgery*. – 1998. – Vol. 118, No. 3. – P. 167-171.

27. Okhunov A. Influence of a granulocyte-colony-stimulating factor on the cytological picture of the wound in patients with purulent-inflammatory diseases of soft tissues on the background of diabetes mellitus. *Research Square*; 2022. DOI: 10.21203/rs.3.rs-2304237/v1.

28. Okhunov A. O., and D. N. Korikhonov. "DIFFERENTIAL DIAGNOSIS OF NECROTIZING FASCIITIS." *British Medical Journal* 3.1 (2023).

29. Okhunov A. O., and F. M. Abdurakhmanov. Ways to achieve positive results of dermaplasty in patients with diabetic foot syndrome.// *British Medical Journal* 3.1 (2023).

30. Okhunov A.O. Endovascular methods for correcting angiopathy of the diabetic foot syndrome in patients after COVID-19 // 16th European Diabetes and Endocrinology Congress – 2022, P.12-15.

31. Okhunov A.O. Prediction and prevention of sepsis in patients with necrotizing fasciitis on the background of diabetes mellitus // 42-Annual Meeting of the Surgical Infection Society, Westlake Village, CA, 2023, April 11-14, P.39.

32. Okhunov A.O., Abduralhmanov F.M. Prolonged intraarterial catheter therapy for diabetic gangrene of the lower limb // 42-Annual Meeting of the Surgical Infec-

tion Society, Westlake Village, CA April 11-14, 2023 – P.38

33. Our experience in the treatment of Fournier's disease in diabetes mellitus / S. A. Abdullaev, D. A. Djalolov, A. F. Abdurakhimova [et al.] // *Academy*. – 2021. – No. 6(69). – P. 60-62.

34. Post-surgical zygomycotic necrotizing subcutaneous infection caused by *Absidia corymbifera* / G. P. Thami, S. Kaur, A. S. Bawa [et al.] // *Clinical & Experimental Dermatology*. – 2003. – Vol. 28, No. 3. – P. 251-253.

35. Problems of surgical tactics for the treatment of diabetic foot syndrome / S. Abdullaev, A. T. A. Akhmedov, D. Djalolov // *International Journal of Advanced Science and Technology*. – 2020. – Vol. 29, No. 5. – P. 1836-1838.

36. Rapidly Fatal Necrotizing Fasciitis After Aesthetic Liposuction / Ch. Heitmann, Ch. Czermak, G. Germann // *Aesthetic Plastic Surgery*. – 2000. – Vol. 24, No. 5. – P. 0344-0347.

37. Some dimensions of infusion-transfusion treatment of sepsis in diabetes mellitus / S. A. Abdullaev, S. Sh. Valieva, A. F. Abdurakhimova, D. A. Jalolov // *Herald of Science and Education*. – 2021. – No. 15-2(118). – P. 40-44.

38. Streptolysin S and necrotising infections produced by group G streptococcus / D. Humar, V. Datta, D. J. Bast // *The Lancet*. – 2002. – Vol. 359, No. 9301. – P. 124-129.

39. Subacute Necrotizing Fasciitis Caused by Gas-Producing *Staphylococcus aureus* / W. R. Saliba, L. H. Goldstein, R. Raz, et al. // *European Journal of Clinical Microbiology & Infectious Diseases*. – 2003. – Vol. 22, No. 10. – P. 612-614.

40. Therapeutic tactics in the deep forms of rectal abscesses complicated by Fournier gangrene / O. E. Kanikovskiy, A. V. Osadchyi, S. I. Androsov, et al. // – 2020. – Vol. 73, No. 2. – P. 293-297.

41. Validation of figs scores in predicting Fournier gangrene in tertiary hospital / B. S. Noegroho, S. Siregar, A. Mustafa, M. A. Rivaldi // *Research and Reports in Urology*. – 2021. – Vol. 13. – P. 341-346.

42. Varicella-associated necrotizing fasciitis in a child / A. Groger, D. Ulrich, F. Unglaub, N. Pallua // *Der Unfallchirurg*. – 2004. – Vol. 107, No. 4. – P. 325-327.

NEKROTIZING FASCIITIS ETIOLOGIYASI BO'YICHA ZAMONAVIY MA'LUMOTLAR

D.N. Qoryhonov
Toshkent tibbiyot akademiyasi

Nekrotizatsiya qiluvchi fasciit - bu yuqtiruvchi fascial tuzilmalarning yuqumli kasalligi bo'lib, uning kelib chiqishi yuqumli vositaning shikastlangan teri orqali aylanib yuruvchi qonga (qon aylanishi infeksiyasiga) kirib borishi bilan bog'liq. Infektsion manbai chayqalishlar, jarohatlar, jarohatlar, shu jumladan operatsionlar, shu jumladan laparoskopiya, kuyishlar va turli organlarning yiringli kasalliklari bo'lishi mumkin. Nekrotizatsiya qiluvchi fasciitni makroorganizm bilan boshlang'ich mikrob omilining o'zaro ta'sir mexanizmi yumshoq to'qimalarning banal yuqumli kasalliklari patogenezidan tubdan farq qiladi. Ushbu maqolaning maqsadi turli nashrlardan olingan ma'lumotlar va o'z kuzatishlarimizni tahlil qilish asosida nekrotizatsiya qiluvchi fasciitning mikrobiotasini xarakterlashdir.

Tayanch iboralar: nekrotizatsiyalovchi fasciit, etiologiya, mikroflora, sepsis

СОВРЕМЕННЫЕ СВЕДЕНИЯ ОТНОСИТЕЛЬНО ЭТИОЛОГИИ НЕКРОТИЧЕСКОГО ФАСЦИИТА

Д.Н. Корихонов
Ташкентская Медицинская Академия

Некротизирующий фасциит - это инфекционное заболевание фасциальных структур, происхождение которого связано с проникновением инфекционного агента в циркулирующую кровь (инфицирование циркулирующей крови) через поврежденную кожу. Источником инфицирования могут быть ссадины, потертости, раны, в том числе и операционные, включая лапароскопию, ожоги, а также гнойные заболевания различных органов. Механизм взаимодействия микробного фактора, инициирующего некротизирующий фасциит, с макроорганизмом принципиально отличается от патогенеза банальных инфекционных заболеваний мягких тканей. Целью данной статьи является охарактеризовать микробиоты некротизирующего фасциита на основании данных различных публикаций и анализа собственных наблюдений.

Ключевые слова: некротизирующий фасциит, этиология, микрофлора, сепсис